

CASE REPORT**Osteosarcoma with Sizeable Pleural Deposit Diagnosed on Conventional Bone Scanning****Al Ghamdi H., Wageeh Sh. and Abdel Karim H.**

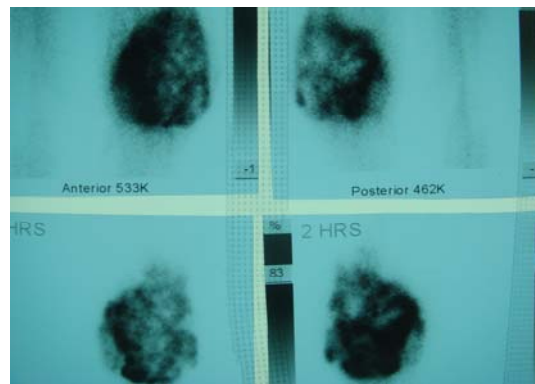
Departments of Oncology and Radiodiagnosis, King Abdel Aziz Hospital and oncology center (KAAH&OC) Jeddah, KSA

A 19 years old girl presented with big swelling in lower left thigh associated with right sided chest pain. Bone scan revealed big hypervascular lesion of intense tracer uptake in a heterogenous pattern with multiple relative photopenic areas and margin disruption located in lower left femur, its scintigraphic features are highly impressive of osteosarcoma (Fig1A). This is associated with multiple variable sized areas of active Tc99m MDP uptake in both lung fields, more on the right side. One of the chest lesions is seated in lower outer right chest, it has a triangular shape with the apex down, it is seated at peripheral right hypochondrial region (Fig1B). SPECT data confirmed presence of multiple Tc99m MDP avid pulmonary deposits with lower right sizeable pleural deposit (Fig2). Post contrast CT scan of the left thigh revealed presence of huge left thigh mass lesion with mainly extraosseous extension encircling the left femoral shaft originating from the distal left femoral metaphysis showing extensive ossification and new bone

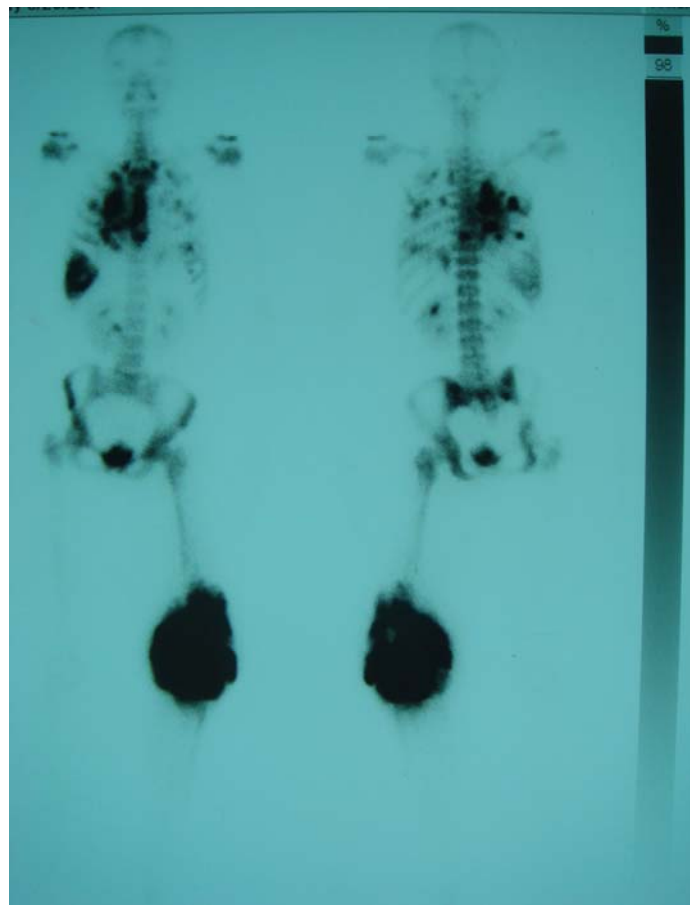
formation (Fig3). Post contrast CT chest showed multiple right pulmonary masses with calcification/ossification and areas of breakdown associated with loculated effusion. There is associated contralateral mediastinal shift and small non ossified left pulmonary deposit (Fig4). CT scan also showed spindle shaped pleural based mass lesion in right side. Biopsy from the primary lesion confirmed the diagnosis of primary osteosarcoma, with imaging modalities showing pulmonary and pleural deposits that are highly avid to bone seeking radiopharmaceutical at first presentation. To our knowledge, This is one of the few cases of untreated osteosarcoma presenting with synchronous pulmonary metastases and pleural deposit highly avid to Tc99m MDP, showing intense tracer uptake in conventional bone scanning and confirmed by SPECT images.

Corresponding Author**Sherin Wagih, MD.****E-mail:** dr_sherinwagih@hotmail.com

Ant.Post.



(A) Lower thighs: blood pool images (upper row) - late static images(lower row).



(B) Tc99m MDP whole body bone scan

Fig 1: Bone scan: (A) Early blood pool (5min.)and late (2h.) spot views showing hypervascular primary osteosarcoma of lower left femur(B) Whole body scan with multiple pulmonary and lower right pleural deposits highly avid to Tc99m MDP.




Fig 2 : SPECT images of the chest confirming presence of lower right pleural deposit and multiple pulmonary metastases highly avid to Tc 99m MDP .

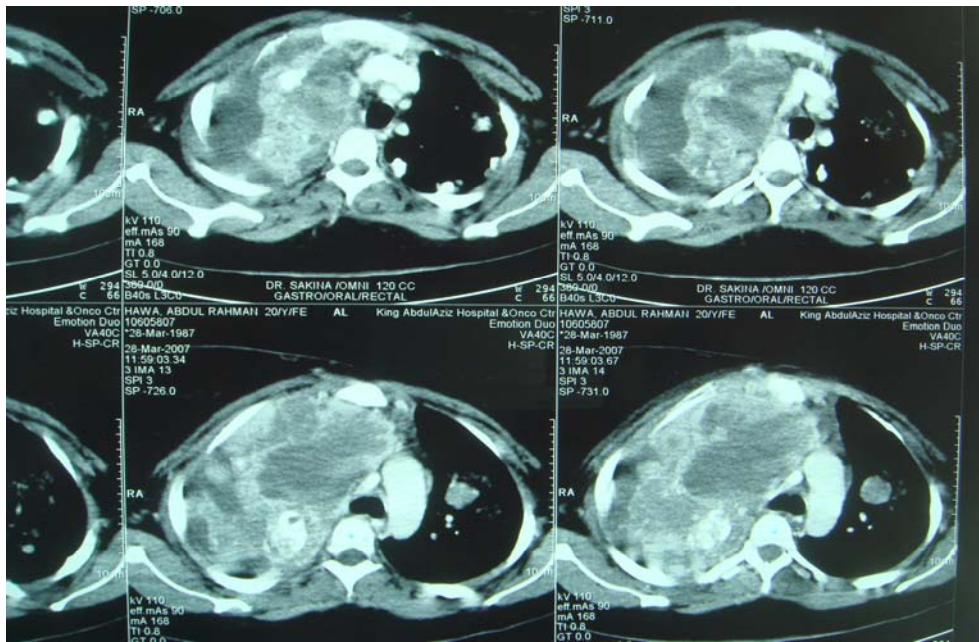


Fig 3 : CT chest showing multiple right pulmonary deposits with contralateral mediastinal shift and small left lung deposit.

Discussion

Osteosarcoma is the most common primary malignant bone tumor in children and adolescents. It is a highly aggressive neoplasm typically composed of spindle cells producing osteoid.⁽¹⁾

Osteosarcoma typically presents between five and thirty years of older. The age of our patient in the current case report is 19 years. There is no significant gender preponderance in patients affected by osteosarcoma, although the incidence has been described as being slightly more frequent in males (1.5:1)⁽³⁾

Most patients with osteosarcoma present with pain and swelling in the involved region and usually seek medical attention following trauma or vigorous physical exercise, both of which are common in this population⁽⁴⁾. In our patient the lesion is seated at distal femur. However, osteosarcoma can also occur in the axial skeleton (<10% of cases in the pediatric age group), commonly the pelvis⁽⁵⁾ Approximately 15%–20% of patients present with radiographically detectable metastases at time of presentation⁽⁶⁾ However, since about 80% of patients with localized osteosarcoma develop metastatic disease following surgical resection virtually all patients are presumed to have subclinical, microscopic metastases⁽¹⁾ The most frequent site for metastatic presentation is the lung, but respiratory symptoms only develop with extensive involvement. However, metastases can also occur in other bones and soft tissues⁽²⁾. Arguably, presentations with multiple bone metastases may actually represent multifocal primary tumors. When osteosarcoma is widely metastatic, more frequently at recurrence than at the time of initial diagnosis, it can spread to the central nervous system or other sites⁽¹⁾. Lung metastases from osteosarcoma also may be occasionally associated with lesions in bone, brain, chest wall, lymph node, skin, pleura and Peritoneal metastases, however, are very rare in osteosarcoma⁽¹⁾. It was suggested

that chemotherapy or radiation therapy may have changed the metastatic pattern of osteosarcoma after prolonged survival⁽⁷⁾. This particular patient actually presented with synchronous pulmonary metastases associated with sizeable pleural deposit.

As regards pleural metastases, Takeshi et al⁽⁸⁾ reported two patients with osteosarcoma associated with pulmonary deposits that migrated to the parietal pleura due to contact. The first patient was a 16-year-old male who had a pleural metastasis in the diaphragm within an area in contact with a single lung metastasis. The second patient was an 11-year-old female with a pleural metastasis of osteosarcoma which was within an area in contact with a single lung metastasis, which had been resected 4 months before. They concluded that a lung metastasis of osteosarcoma occasionally metastasizes to the pleura due to contact; and that this kissing metastases of osteosarcoma could be cured by a complete resection. They advised that the intrathoracic cavity should be thoroughly observed for pleural metastases in those patients.⁽⁸⁾

CT scan is the most common investigation done to evaluate the chest in patients with osteosarcoma with the highest sensitivity for detection of intrathoracic metastatic deposits, it was reported that there seems to be a superiority of spiral CT in the detection of pulmonary metastases from malignant primary bone tumors as compared with FDG-PET. However, specificity of FDG-PET is high, to confirm abnormalities seen on thoracic CT scans as metastatic⁽⁹⁾. The most common radiological appearance of pulmonary metastases from osteosarcoma is presence of multiple well-defined nodules in the lung parenchyma. However, a variety of atypical locations and presentations of osteosarcoma metastases can occur in the

thorax. Rastogi et al, 2008⁽¹⁰⁾ reviewed the thoracic CT findings in 16 patients, with histopathologically confirmed osteosarcoma, with unusual thoracic manifestations out of a total 136 with osteosarcoma patients who done a chest CT scan. Unusual imaging findings included a solitary large ossified lung mass, ossified mediastinal and hilar lymph nodes, an esophagomediastinal fistula, lymphangitic carcinomatosis, pulmonary artery tumor emboli, a solitary large pleural deposit along the major fissure, multiple pleural deposits, diffuse pleural calcification, pneumothorax, diaphragmatic deposits, an isolated chest wall deposit without lung involvement, and primary osteosarcoma of the rib. They reported that findings of lymphangitic carcinomatosis as well as calcified mediastinal lymphadenopathy leading to esophageal fistula are unique in the literature, and there are only a few case reports of these other findings.⁽¹⁰⁾

Skeletal scintigraphy is indispensable in diagnosis of osteosarcoma, in the primary lesion, vascularity and tracer accumulation are almost always markedly increased, but the distribution characteristically demonstrates a patchiness of areas of decreased accumulation within the overall high uptake. The bony outline usually shows marked distortion and the margins of the lesion are very much ill defined. This description is exactly the scintigraphic features of the primary lesion in our reported case (Fig1A). In some patients there is a more circumscribed abnormality in which the accumulation is uniform but markedly increased and associated with greatly increased vascularity. SPECT may be also very useful in localizing precisely the different siting of paraosteal and periosteal osteosarcoma. As regards primary bone tumors, despite the tendency for typical appearance observed in each tumor, there is no unique pattern for any and scintigraphy can be used as the sole investigation, indeed

photopenia has been reported to be associated with osteogenic sarcoma. Detection of remote metastases is an important indication for bone scanning, osseous metastases were reported in 43% of patients. Another study reported 23% incidence of initial bone deposits. Pulmonary metastases remain more common, developing in 52% -60% of patients⁽¹¹⁾.

It is well known that extraosseous uptake of Tc99m diphosphonate compounds can occur in malignant tumors. Extraosseous uptake of Tc99m MDP has been reported in lung cancer, neuroblastoma, breast cancer, metastatic liver tumors, osteosarcoma and ganglioneuroblastoma as well as in some benign tumours, such as lipomas, neurofibromas, angiomyolipomas and haemangiomas. This can also occur in metastases of liver tumours, seminomas, tumors of the spleen and pleural metastases⁽¹²⁾.

There is however divergence of opinion regarding the frequency of uptake of Tc99m MDP in pulmonary metastases. Hoefnagel et al⁽¹³⁾ reported diphosphonate uptake in 11 of 12(91.6%) patients with pulmonary deposits. Two being noted by scintigraphy prior to X – ray tomography. On the other hand, others observed uptake in metastases in only 5 out of 29(17.2%) patients and in 4 out of 28(14.3%) patients with lung metastases. The unreliability of the use of skeletal scintigraphy in the identification of extraosseous metastatic disease was clearly demonstrated even using SPECT⁽¹¹⁾.

The mechanism by which extraosseous uptake of Tc99m diphosphonate compounds occurs has not yet been explained. It has been suggested that there

may be ionic exchange at the crystalline surface of an area of calcification. As there are some cases in which extraosseous uptake is noted without calcification, other mechanisms have been suggested, such as acceleration of calcium metabolism in tissues and tumours, alteration in vascularity and capillary permeability and an increase in the calcium level in ischaemic cellular tissues. It has also been suggested that Tc99m diphosphonate compounds may deposit on the surface of the hydroxyapatite of intracellular mitochondria and may combine with denatured protein, hormone and enzymatic receptors, and that both iron and immature collagen are deposited in the soft tissues that showed tracer uptake. It was postulated that no single mechanism can be responsible and often there may be interaction of two or more mechanisms ⁽¹²⁾.

To our knowledge this is one of the few case reports of untreated huge osteosarcoma of the thigh presenting with synchronous pulmonary metastases associated with big pleural deposit that exhibit intense Tc99m MDP uptake diagnosed by conventional bone scanning in planar images and confirmed by SPECT data.

Grohn et al in 2004 ⁽¹⁴⁾, reported a case of a 23-year-old woman with widespread deposits from osteosarcoma including skeletal, pulmonary and pleural metastases, who had a remarkable response to combined chemo- and radiotherapy, she presented with a swelling of the right thigh, severe generalized pain and progressive left hemiparesis. Radiological examination revealed osteolytic lesions in the cervical spine. CT scan of the chest showed

multiple pulmonary metastases and a huge left pleural effusion. Bone scan showed intense uptake of the radiopharmaceutical in the distal right femur, generalized deposits throughout the skeleton and in the hemithorax corresponding to the lung findings.

Metastatic lesions with the same pattern of diphosphonate uptake were also reported by Othman and El-Desouki in 2003 ⁽¹⁵⁾ in a previously treated 40-year-old woman who is a known case of osteogenic sarcoma of the right leg and underwent below knee amputation. The preoperative workup was negative for distant metastases, and the patient was followed regularly. Two years later she developed dyspnea and chest pain. Computed tomography revealed diffuse left lung metastases with pleural involvement and nodular metastases in the right lung. Whole-body bone scanning revealed the amputated right leg with a clean stump but with widespread metastases in the right thigh involving soft tissue and bone, bony pelvis, left femur, and skull. In addition, diffuse left lung metastases involving both parietal pleura and lung parenchyma were seen. They reported that Tc-99m methylene diphosphonate uptake has been observed in the soft tissue and lungs in patients with osteogenic sarcoma but is rarely observed in practice with this degree of aggressiveness as seen in their particular patient ⁽¹⁵⁾.

References

1. Marina N, Gebhardt M, Gorlick LTR: Biology and therapeutic advances for pediatric osteosarcoma. *The Oncologist*, Vol. 9, No.4, 422–441, 2004.
2. Tan JZ, Schlicht SM, Powell GJ, Thomas D, Slavin JL, Smith PJ, and Choong P FM: Multidisciplinary approach to diagnosis and management of osteosarcoma – a review of the St Vincent's Hospital experience. *Int Semin Surg Oncol.*; 3: 38, 2006
3. Di Caprio MR, Lindskog DM, Husted D, Reith J, Scarborough MT.: Knee Pain in a 14-Year-Old Girl. *Clinical Orthopaedics and Related Research.*; 435:267–275, 2005.
4. Rosen G, Forscher CA, Mankin HJ: Neoplasms of bone and soft tissue: Bone tumors. In: *Cancer Medicine* ;eds. Bast RCJ, Kufe DW, Pollock RE, Surg; 12:129-132, 2006 Fifth Edition. Hamilton, Canada: B.C. Decker, Inc.: 1870–1902, 2000.
5. Estrada-Aguilar J, Greenberg H, Walling A.: Primary treatment of pelvic osteosarcoma. Report of five cases. *Cancer*; 69:1137–1145, 1992.
6. Kaste SC, Pratt CB, Cain AM L.: Metastases detected at the time of diagnosis of primary pediatric extremity osteosarcoma: imaging features. *Cancer*; 86:1602–1608, 1999.
7. Marina NM, Pratt CB, Shema SJ.: Brain metastases in osteosarcoma. Report of a long-term survivor and review of the St. Jude Children's Research Hospital experience. *Cancer*; 71:3656–3660, 1993.
8. Mori TK, Yoshioka M, Iwatani K, Kobayashi H, Yoshimoto K, and Nomori H.: Kissing pleural metastases from metastatic osteosarcoma of the lung. *Ann Thoraco cardiovasc*
9. Franzius C., Daldrup-Link HC., Sciuk J., Rummeny EJ., Bielack S., Jürges H., Schober O: FDG-PET for detection of pulmonary metastases from malignant primary bone tumors: comparison with spiral CT. *Ann Oncol.*; 12(4):479–86, 2001.
10. Rastogi R; Garg R; Thulkar S; Bakhshi S; Gupta A: Unusual thoracic CT manifestations of osteosarcoma: review of 16 cases. *Pediatr Radiol.*; 38 (5):551-8, 2008.
11. Charron, M and Brown M.L.: Primary and metastatic bone disease. In: *Diagnostic nuclear medicine*. eds. Sandlerm., Coleman R., Patton J., Wackers T. and Gattshalk A., 413-428, 2003.
12. Kaida H, Ishibashi M, Baba K, Nishida H, Matsuoka K, and Hayabuchi N, Extraosseous uptake of metastatic lymph nodes of ureteral cancer on 99mTc hydroxymethylene diphosphonate bone scintigraphy *British Journal of Radiology* 77, 869-870, 2004.
13. Hoefnagel CA, Bruning PF, Cotton P, Marcuse HR, Van Der Schoot JB.: Detection of lung metastases from osteosarcoma by scintigraphy using 99m-Tc-methylene-diphosphonate. *Diag Imaging*; 50:277-284, 198.
14. Grohn P, Uttamchandani A, Al-Haider Z, Adams B: A Case Report: Successful Management of a Widespread Osteosarcoma. *Med Princ Pract*; 13:54-56, 2004.
15. Othman S, El-Desouki M.: Bone scan appearance in aggressive osteogenic sarcoma with pleural, lung, bone, and soft tissue metastases. *Clin Nucl Med.*; 28 (11): 926, 2003.