

**Oncology, Original Article****Role of  $^{18}\text{F}$ -FDG - PET/CT in Patients with Differentiated Thyroid Cancer Who Present with Elevated Thyroglobulin and Negative  $^{131}\text{I}$  Whole Body Scan****Moustafa HM\*, Taalab KM\*\* Khalil HF\*, Elhennawy AM\*\*\*,***\* NEMROCK, faculty of medicine, Cairo University**\*\* International Medical Center, Egypt**\*\*\* Elgalaa Armed Forces Hospital***ABSTRACT**

**Aim of the work:** To detect the ability of  $^{18}\text{F}$ -FDG with PET/CT to explain the elevated Tg levels in patients with negative  $^{131}\text{I}$  whole body diagnostic dose scan and to correlate of  $^{18}\text{F}$ -FDG with PET/CT with other diagnostic methods and histopathologic diagnosis.

**Patients and methods:** 20 patients (13 males and 7 females) with pathologically proven differentiated cancer thyroid were included in the study. All patients were subjected to near total thyroidectomy. 8 out of the 20 patients also underwent lymph node dissection. All received  $^{131}\text{I}$  ablation and had a negative whole body scan during follow up. They had unexplained elevated ( $> 10$  ng/ml or more) or rising serum Tg levels (5-10ng/ml). All patients were subjected to full history, clinical examination, Laboratory and radiological assessment as well as  $^{18}\text{F}$ -FDG PET/CT study.

**Results:** Neck US detected 7 lesions in 6 patients, all of them confirmed to be

positive by PET/CT and an additional 13 neck lesions were detected by PET/CT in 15 patients. CT chest detected 8 patients, 6 of them confirmed by PET/CT while 2 lung lesions were negative. Eight additional mediastinal lymph node metastases were detected by PET/CT.

PET/CT showed positive findings in 19/20 patients. In the remaining no cause for the elevated Tg was found with PET/CT or other radiological methods. PET/CT directed the management in 14/20 patients either to surgery or to external radiotherapy with normalization of Tg level within weeks after treatment.

**Conclusion:**  $^{18}\text{F}$ -FDG PET/CT is of undeniable clinical value in patients with negative  $^{131}\text{I}$  whole-body scan results who are suspected of having a metastatic thyroid disease. It is able to detect significantly additional tumor sites than US or CT procedures.

**Key words:** FDG PET/CT, Thyroglobuline, DCT, Iodine-WBS.

## INTRODUCTION:

Differentiated thyroid cancer (Papillary and follicular) represents approximately 80%-85% of thyroid carcinoma. Both have an excellent prognosis, with a 20 years survival of 90%–95% and 75%, respectively [1].

The standard surgical treatment is total (or near-total) thyroidectomy. This procedure decreases the risk of local recurrence and facilitates post-surgical radioiodine ablation and adequate follow up [2].

A diagnostic scan with radio-active  $^{131}\text{I}$  is usually obtained 4-6 weeks after surgery to demonstrate residual functioning thyroid remnant and/or metastases. The diagnostic  $^{131}\text{I}$  dose typically ranges from 2–5 mCi (74-185MBq) and scanning is performed at 72 hours [3].

Serum thyroglobulin (TG) appears to be the most sensitive test in the follow-up of differentiated cancer thyroid while other imaging methods as ultrasound and CT may be helpful with limited sensitivity [4]. The lack of  $^{131}\text{I}$  trapping by metastatic tissue does not allow whole body scintigraphy to visualize metastatic spread accordingly will hinder therapy to treat such metastatic spread. In this view, accurate localizing imaging methodology different from  $^{131}\text{I}$  whole body scintigraphy is required. More favorable results have been reported with  $^{18}\text{F}$ -FDG with PET/CT. The PET/CT hybrid images provide good anatomical localization of the hypermetabolic metastatic lesions [5].

**The aim of this study** is to detect the ability of  $^{18}\text{F}$ -FDG with PET/CT to explain the elevated Tg levels in patients with negative  $^{131}\text{I}$  WBS diagnostic dose. A further secondary aim is correlation of

$^{18}\text{F}$ -FDG PET/CT with other diagnostic methods and final diagnosis.

## PATIENTS AND METHODS:

This retrospective study was performed at the International Medical Center (IMC) during the period from January 2009 to December 2011.

This study included 20 patients (13 males and 7 females) with pathologically proven differentiated cancer thyroid. All patients underwent near total thyroidectomy. 8 out of the 20 patients underwent local lymph node dissection. All received  $^{131}\text{I}$  ablation and they had negative whole body scan during follow up, The WBS was performed administration of 2-5mCi (74-185MBq)  $^{131}\text{I}$  orally, after 3-4 weeks cessation of Eltroxin. Also, included subject patients had unexplained elevated TG (> 10 ng/ml or more) or rising serum Tg levels (5-10 ng/ml).

The patients had a full history and clinical examination, especially the neck.

Laboratory and radiological done including Serum Tg level (with Tg antibody estimation), Fasting blood sugar to determine if the patient is diabetic, neck ultrasound and chest CT.

### **PET/CT imaging:**

PET/CT was performed on an integrated 64 slice PET/CT scanner (Philips; Eindhoven, Netherlands).

Patients were fasting for at least 6 hours before the PET/CT study. PET images were acquired during normal breathing in 3D mode for 4 minutes per

bed position 60 minutes after intravenous administration of 0.1 mCi (3.7MBq  $^{18}\text{F}$ -FDG /Kg.

Interpretation of PET/CT scans were done independently by 2 experienced physicians blinded to the clinical situation and any disagreement was resolved by consensus.

PET and fused PET/CT images were analyzed both qualitatively and semi quantitatively.

**Qualitative evaluation:** A visually abnormal focus of  $^{18}\text{F}$ -FDG uptake was defined as focal uptake higher than surrounding tissue with no similar contralateral activity.

**Semi-Quantitative evaluation:**

A SUV max < 3 was considered normal while > 3 was considered abnormal.

**Follow up:**

Patients have been followed up clinically and the Tg level was estimated periodically at 6 months interval. Patients who underwent any changes in the Management in the form of either surgery or external radio-therapy, Tg was measured 4-6 weeks after management.

Follow up neck US, CT chest and PET/CT were done according to each patient status.

**Statistical analysis:**

Comparison of results of PET/CT with US and CT was done on both patients and a lesion by lesion basis.

**RESULTS:**

**Thyroglobulin:**

All patients had elevated serum Tg level and negative anti Tg Abs. Tg was highly elevated (>10 ng/ml) in 14 patients and raised (5-10 ng/ml) in 6 patients (Table 1, Fig 1).

In The PET/CT scan finding showed that in 6 patients with raised level of Tg (5-10 ng / ml), 4 showed loco-regional recurrence, while 2 patients had metastatic disease. Ten of 14 patients with Tg > 10 ng/ml had metastatic disease, while 3 patients showed loco-regional recurrence and only one patient was negative on PET/CT (Table 1, Fig 1).

**Table (1): Correlation of PET/CT findings with Tg levels:**

<i>Tg level (ng/ml)</i>	<i>No. of Pts.</i>	<i>Loco-regional</i>	<i>Metastatic</i>
5-10	6	4 Pts (67%)	2Pts (33%)
10 – 100	13	3 Pts (23%)	9Pts (69%)
>100	1	-	1Pts

**N.B: One patient with elevated Tg (10-100 ng/ml) was negative on PET/CT.**

**Radiological findings:**

**A) Neck ultrasound** Neck ultrasound was positive in 6/20 patients with cervical lymphadenopathy (Fig 1). One of these patients also had local recurrence in the thyroid bed.

**B) CT finding** There were positive findings on CT in chest in 8 patients

(6 patients with lung lesions and 2 patients with mediastinal lymphadenopathy). Two of the lung lesions were negative in PET/CT, while the other 6 lesions were positive on PET/CT (Table 2).

**Table (2): Radiological Findings in 20 patients with DCT:**

<b>Neck US</b>	LN	6/20	30%
<b>CT chest</b>	Lung	6/20	30%
	Mediastinal LN	2/20	10%

NB: One of the 6 US positive patients showed both cervical LNs and also local recurrence.

**C) PET/CT findings:**

The 18F-FDG PET/CT showed positive findings in 19/20 patients evaluated PET/CT showed that 7 patients had loco-regional disease and 12 patients had metastasis lesions. Among the 12/20

patients that showed metastatic lesions on PET/CT, 17 sites of metastases were detected with the most common site being in the mediastinal lymph nodes (Table 3 Fig 2).

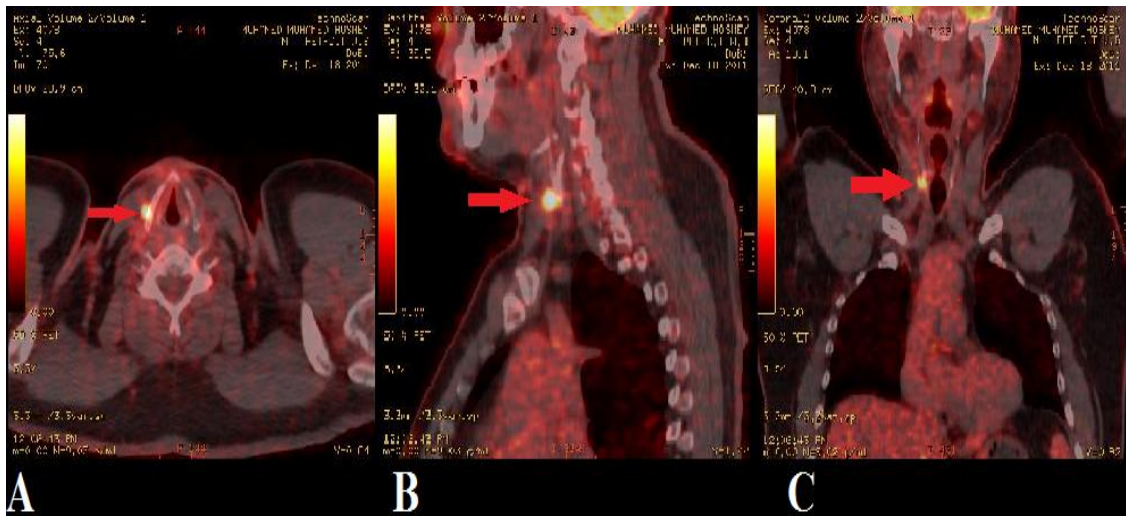
**Table (3): Distribution of 17 sites of metastatic lesions detected with PET/CT in 12 patients with DCT:**

<b>Metastatic</b>	Mediastinal LN	10/12	83%
	Lung	4/12	33%
	Bone	2/12	16%
	Liver	1/12	8%

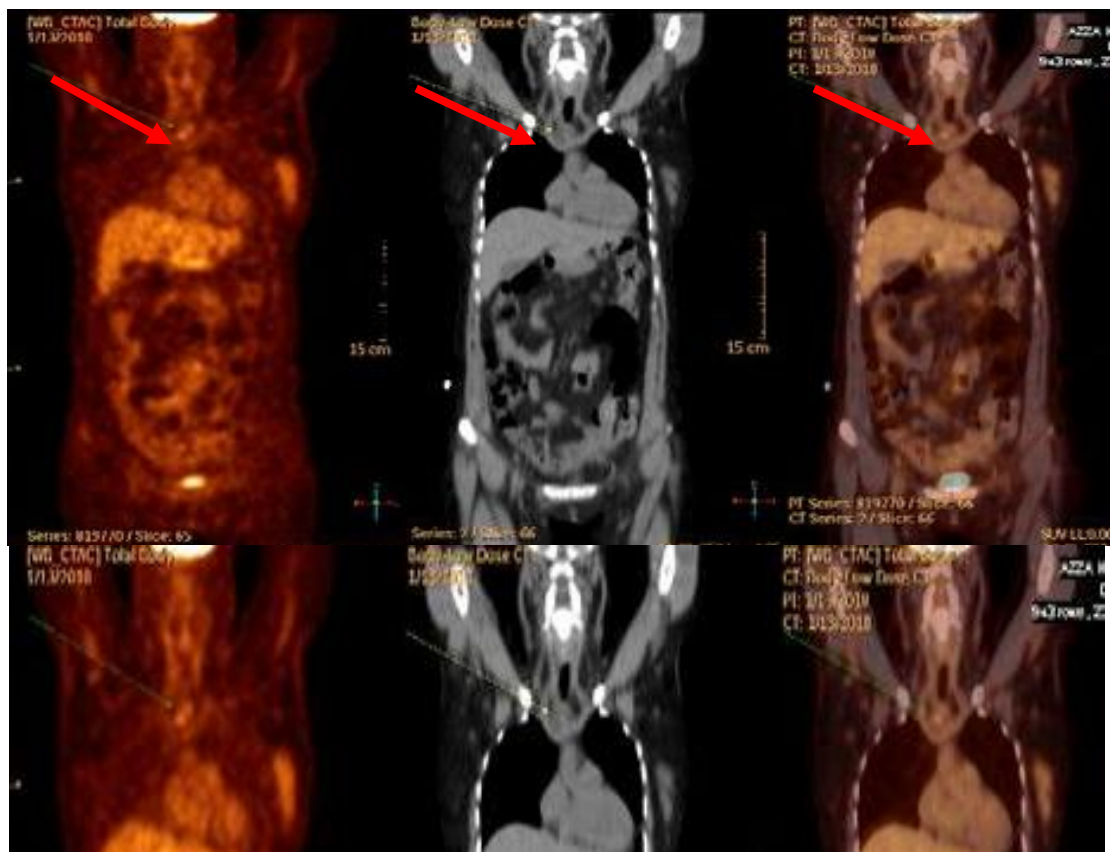
NB: Some patients had multiple metastatic lesions at different sites.

PET/CT was positive in 10 patients with nodal metastases, 5 patients with pure nodal lesions while 4 others with nodal

and lung lesions and only one patient with nodal and skeletal lesions.



**Figure 1.** Transverse, B. Sagittal, C. Coronal images showing Local residue/recurrence at thyroid operative bed (arrowed) in a 47 year old male.



**Figure 2:** Coronal Section showing peri-tracheal LN FDG-avid lesion in a 45 year old female with normal neck ultrasound

**Comparison of PET/CT findings with US and CT.**

US identified 7 neck lesions on 6 patients with 20 lesions seen on PET/CT in 15 patients. PET/CT found all the neck lesions seen on US and an additional 5 lesions in the cervical LNs and 8 local recurrent lesions in other sites in the neck region.

PET/CT found 14 metastatic lesions in the chest of 12 patients compared with 8 lesions detected by CT chest. PET/CT found 8 sites of active disease in the mediastinal LNs, CT found 2 lung lesions not detected by PET/CT (Table 4).

**Table (4): Comparison of PET/CT, neck US and CT chest findings regarding number of lesions.**

			PET/CT		
			Confirmed	Not active	Additional lesions
Neck US	Cervical LN	6	6	-	5
	Local Recurrence	1	1	-	8
CT chest	Lung	6	4	2	-
	Mediastinal LN	2	2	-	8

**Follow up and outcomes of PET/CT findings:**

PET/CT directed clinical management in 14/20 patients with favorable outcomes. 7 patients with only cervical LNs lesions had this was followed by normalization of Tg level 4-6 weeks after surgery. 5 other patients with only mediastinal LNs metastases and 2 patients with skeletal metastases were underwent external radiotherapy (30 – 40 Gy in 3-4 weeks) with a reduction of Tg level within 6 weeks.

The patient with hepatic metastasis died within 6 months, while the remaining 4 patients with multiple metastatic lesions were lost in the follow up.

The only patient with no apparent explanation of elevated Tg neither on US, CT nor PET/CT showed unexplained spontaneous redaction of Tg in the follow up.

## DISCUSSION

Treatment of DCT includes thyroidectomy and radioiodine ablation. A rising Tg following complete ablation is generally a reliable indicator of recurrent thyroid cancer. It assumed the presence of disease in patients with persistent elevated or rising Tg levels, although this assumption might not be true in all cases [2].

An advantage of  $^{18}\text{F}$ -FDG PET/CT whole body scanning is the ability with identification of thyroid cancer recurrences and metastases in soft tissue, lymph nodes, liver, lungs, and bone in a single imaging procedure. A crucial advantage of co-registered  $^{18}\text{F}$ -FDG PET/CT is the precise localization of local recurrences and distant metastatic disease [1].

In this work we found an overall high sensitivity of PET/CT for detecting and localizing recurrent or metastatic differentiated thyroid cancer (19/20 patients). Only one patient showed no possible explanation for the elevated Tg level neither on US, CT nor PET/CT. However, this patient showed reduction of Tg level in the follow up. These results compare favourably with a study of **Schluter et al** 64 DCT patients, 44 patients had positive PET/CT scans, which were proven to be true-positive in 34 patients, whereas 10 patients had false-positive findings. On the other hand, 20 patients had negative scans. These were true-negative findings in 5 patients, whereas the remaining 15 patients had false-negative results [6].

In the present study, PET/CT was positive in 15 patients more superior than ultrasound in local recurrence. Though an important observation is that ultrasound offers the advantage of immediate biopsy of suggestive lesions [7].

Also we demonstrated that 8 patients had positive findings in CT chest (6 lung lesions and 2 mediastinal LNs lesions), 2 of the lung lesions were negative in PET/CT, while the other 6 lesions approved to be active on PET/CT. PET/CT was positive in 12 patients with 17 sites of metastatic lesions. Similar findings was reported in a study of **Helal et al** 37 patients with DCT using  $^{18}\text{F}$ -FDG PET/CT, positive findings were evident in 28 of the 37 patients (76%) and CT findings were positive in 10 patients (27%). FDG confirmed 17 of 18 known tumor sites and detected an additional 11 sites [8]. **Zoller et al** of 47 imaged with  $^{18}\text{F}$ -FDG PET/CT scans of patients with a history of DCT, elevated Tg levels and negative  $^{131}\text{I}$  uptake 35 investigations (74%) revealed pathological FDG-PET/CT findings. 25 with local recurrences, 62 lymph node metastases and 122 organ metastases (41 lung, 60 bone and 21 other organs) were diagnosed [9].

In follow up of our patients, PET/CT directed the management at 14/20 patients with favorable outcomes. 7 patients with only cervical LNs lesions were subjected to surgery and excision

of the affected LNs, this followed by normalization of Tg level 4-6 weeks after surgery. 5 patients with only mediastinal LNs metastases and 2 patients with skeletal metastases were subjected to external radiotherapy with reduction of Tg level within 6 weeks. In a **Schluter et al** study treatment was changed in 22 of 34 patients imaged with  $^{18}\text{F}$  FDG. 18 patients had further surgery, and 4 patients were referred for external

irradiation. FDG PET showed widespread disease in 7 patients; thus, palliative treatment, rather than curative therapy, was initiated [6].

## CONCLUSION

PET/CT had added value in patients with negative  $^{131}\text{I}$  WBS in detection of local recurrence or metastatic lesions not detected by other diagnostic methods.

## REFERENCES

- 1.Sipos, J.A. and E.L. Mazzaferri, Thyroid cancer epidemiology and prognostic variables. *Clinical oncology*, 22 (6): p. 395-404; 2010.
- 2.Pacini, F., Management of differentiated thyroid cancer of the follicular epithelium. *Annals of medicine*; 2011.
- 3.Malandrino, P., et al., Risk-adapted management of differentiated thyroid cancer assessed by a sensitive measurement of basal serum thyroglobulin. *The Journal of clinical endocrinology and metabolism*, 96 (6): p. 1703-9; 2011.
- 4.Zakani, A., et al., Evaluation of radioiodine therapy in differentiated thyroid cancer subjects with elevated serum thyroglobulin and negative whole body scan using  $^{131}\text{I}$  with emphasize on the thallium scintigraphy in these subgroups. *European review for medical and pharmacological sciences*, 15(10): p. 1215-21; 2011.
- 5.Lin, E., et al., PET and PET/CT : a clinical guide. 2nd ed. ed, New York: Thieme; 2009.
- 6.Schluter, B., et al., Impact of FDG PET on patients with differentiated thyroid cancer who present with elevated thyroglobulin and negative  $^{131}\text{I}$  scan. *Journal of nuclear medicine : official publication, Society of Nuclear Medicine*,. 42 (1): p. 71-6; 2001
- 7.Wong, K.T. and A.T. Ahuja, Ultrasound of thyroid cancer. *Cancer imaging : the official publication of the International Cancer Imaging Society*,. 5: p. 157-66; 2005.
- 8.Helal, B.O., et al., Clinical impact of (18)F-FDG PET in thyroid carcinoma patients with elevated thyroglobulin levels and negative ( $^{131}\text{I}$ ) scanning results after therapy. *Journal of nuclear medicine : official publication, Society of Nuclear Medicine*,. 42(10): p. 1464-9; 2001.
- 9.Zoller, M., et al., Combined PET/CT in the follow-up of differentiated thyroid carcinoma: what is the impact of each modality? *European journal of nuclear medicine and molecular imaging*,. 34 (4): p. 487-95; 2007.