

Oncology, Original Article**FDG-PET/CT in Management of Head and Neck Cancers: Is it Mandatory to do Whole Body Scan?****Farghaly,H*, Kassem,H**,Alobaid,H****

**Department of Clinical Oncology and Nuclear Medicine, Assiut University, Assiut, Egypt. **Nuclear Medicine Division.Radiology Department, Prince Sultan military Medical city, Riyadh, Saudi Arabia.*

ABSTRACT

Objectives: To re-verify the value of whole body (WB) PET/CT in management of head and neck cancer (HNC) and to assess the clinical feasibility of limited above diaphragm PET/CT. **Material and Methods:** Retrospectively we reviewed 200 WB PET/CT scans of 180 patients with HNC (15-81 years, average 53.1±12.5, 132 male and 48 female) in our institution from Dec. 2009 to August 2012. These include 100 patients' nasopharyngeal carcinomas (NPC) and 80 head and neck squamous cell carcinomas (HNSCC). The HNSCC include 28 oral cavity, 15 larynx, 17 oropharynx, 5 nasal, 5 maxillary, 7 hypopharynx and 3 submandibular. In each scan, the lesions below the diaphragm were recorded and correlated with available pathological

result, imaging modalities or follow-up PET/CT. **Results:** Metastatic lesions from HNC below diaphragm were identified in 9 patients out of 180 (5%). Two patients with HNSCC out of 80 (2.5%) had below diaphragm metastasis. One patient with tongue SCC with metastatic cervical lymph nodes and synchronous rectal cancer had only metastatic osseous lesions (lumbar 2 and 3 vertebrae) below the diaphragm, which proved to be SCC metastasis by biopsy and pathological examination. The other patient had maxillary SCC with lung and liver metastasis. Seven patients out 100 NPC (7%) had metastasis below the diaphragm. Out of these 7 patients with metastatic NPC, 4 patients had hepatic metastasis and porta hepatitis

Keywords: 18F-FDG PET/CT; head and neck cancer; above diaphragm scan.

Corresponding Author: Farghaly,H

Email: hussen2h@yahoo.com

lymph nodes metastasis, 2 patients had both hepatic and adrenal metastasis as seen in FDG PET/CT and CT, one patient had multiple abdominal and pelvic lymph nodes, hepatic, splenic and osseous metastatic lesions. The management of disease was changed based on the findings below the level of diaphragm in one subject (1.25%) with HNSCC (the patient had the primary tongue SCC and cervical lymph nodes with only lumbar metastasis) and two patients (2%) with NP had no metastatic lesions above the level of the diaphragm

Conclusions: We concluded that PET/CT imaging below the level of the diaphragm in HNSCC is of no significant added value. Therefore, performing a more limited protocol (above diaphragm) is suggested. However, WB PET/CT imaging in NPC appears to be the appropriate imaging protocol for this population due to higher yield (10.8 %) of relevant findings below the level of the diaphragm in NPC patients. However, this recommendation requires further evaluation and validation in larger prospective studies.

INTRODUCTION

Head and neck cancer included HNSCC and NPC. HNSCC comprises the vast

majority of HNC. Imaging is an integral part of the clinical management of patients with head and neck cancers. These lesions are typically evaluated with computed tomography (CT) and/or magnetic resonance imaging (MRI). 2-Deoxy-2-[F-18]fluoro-D-glucose (FDG) positron emission tomography and computed tomography (PET/CT) combines the ability to detect metabolically active processes and their morphologic features in a single exam^[1]. Functional imaging with FDG PET has been shown to be useful in the detection of the primary tumor site in patients with metastatic cervical adenopathy, initial staging of disease, differentiation of post-therapy changes from residual and recurrent disease, monitoring of tumor response to therapy, detection of synchronous lung lesions, and in prognostication^[2]. For the previous indications FDG PET/CT usually have been done as whole body technique from top of the head to the mid thigh. However; the standard radiologic staging of malignancy in this region involves imaging the head, neck, chest, and upper abdomen. There is a question raising now "Is there is added value of FDG PET/CT scanning below the level of diaphragm?" There is one study concluded that FDG PET/CT is of no

added value below the level of adrenal in HNSCC [3] and another one concluded that FDG PET/CT is of no added value below the level of the diaphragm in HNSCC [4]. In this study, we evaluated the relative benefit of performing a traditional whole body versus limited above diaphragm PET/CT scan in cases of HNSCC and nasopharyngeal carcinoma.

MATERIALS AND METHODS

Informed consent was not required for this retrospective analysis.

Patient Population: Retrospectively we reviewed 200 whole body FDG PET/CT scans of 180 consecutive patients (60 patients has initial staging PET/CT scans, 100 patients has follow-up PET/CT scans and 20 patients have both initial staging and follow-up scan), (15-81 years, average 53.1 ± 12.5 , 132 male and 48 female) with pathologically proven head and neck cancer in our institution from December 2009 to August 2012. The inclusion criteria were histopathologically proven diagnosis of HNSCC or NPC and availability of whole body FDG PET/CT scans.

PET/CT scanning

Patients fasted at least 4 hours before the tracer injection and received an

intravenous injection (some patients were injected manually and the other by automatic injector) of approximately 5.18 MBq/Kg (0.14 mCi/Kg) of ^{18}F -FDG, with a maximum of 444 MBq (12 mCi). Blood glucose level was measured immediately prior to FDG injection and was < 165 mg in all studied cases. Patients were sitting calm in a quiet injection room without talking during the subsequent 40-60 min of the FDG uptake phase. Patients were allowed to breathe normally during image acquisition without specific instructions. All scans were acquired using a Gemini TF PET/CT scanner (Philips Medical Systems). Time per bed position is 1 min / bed and always in 3D.

CT scanning:

The CT scan of the PET/CT scanner consisted of a 16 slice CT. Gantry allows for a patient port of 70 cm. CT Parameters: It is a single sweep: 120–140 KV and 50–150 mAs (based on body mass index), 0.5 second per CT rotation, Pitch – 1.675:1, Slice thickness is 5mm and 512×512 matrix. CT acquisition was performed before emission acquisition. CT data were used for image fusion and the generation of the CT transmission map. In most of patients oral contrast was used however; no IV contrast was used. Breathing

technique is hold breath after normal expiration. If patient can't do it, then shallow breathing is acceptable.

PET scanning and image processing:

Emission data were acquired for 18-22 bed positions (identical to the CT protocol). Emission scans were acquired at 1 – 3 minutes per bed position, dependent on the body mass index (BMI). The FOV was from the base of the skull to mid thigh with the arms down. If there was a significant truncation artifact from the arms, a localized PET/CT scan in the region of the artifact was done with the arms up. The CT scans were used for attenuation correction purposes and to help in anatomic localization of FDG. The 3-dimensional (3D) WB acquisition parameters consisted of a 128 x 128 matrix and an 18 cm FOV with a 50% overlap. Processing consisted of the 3D Row Action Maximum Likelihood Algorithm (RAMLA) method^[5].

Image analysis:

PET/CT scan or scans of each patient in our study population was reviewed by nuclear medicine physician. Any FDG avid soft tissue or bony lesion below the level of diaphragm which was

confirmed (bone scan, CT and/or MRI) or follow-up FDG PET/CT was recorded and tabulated. All the available non-radionuclide imaging modalities, such as CT and MRI, were reviewed by consultant radiologist. We calculated the percentage of metastatic lesions below the diaphragm in 80 head and neck cancer patients, 100 PET/CT scans, NPC patients and HNSCC patients.

RESULTS

In our study there were 100 patients with pathology proven NPC and 80 patients with pathology proven HNSCC with number and sites of primary tumor shown in table 1.

Metastatic lesions from HNC below diaphragm were identified in 9 patients out of 180 (5%). Two patients out of 80 HNSCC patients (2.5%) had below diaphragm metastatic SCC.

One patient with tongue SCC with metastatic cervical lymph nodes and synchronous rectal cancer had only metastatic osseous lesions (lumbar 2 and 3 vertebrae) below the diaphragm, which proved to be SCC metastasis by biopsy and pathological examination.

Table 1: Number and sites of the primary tumor

Primary tumor	Number
NPC	100
HNSCC	80
Oral cavity	28
Tongue	18
Lips	4
Floor of the mouth	4
Buccal mucosa	2
Larynx	15
Glottis	7
Spurglottis	4
Vocal cord	4
Oropharynx,	17
Tonsil	8
Base of the tongue	5
Soft palate	4
Maxilla	5
Nasal	5
Hypopharynx	7
Submandibular	3

The other patient had maxillary SCC with lung (right lower lobe metastatic nodule and liver metastasis as seen in FDG PET/CT and chest CT and triphasic CT liver.

Lesions below diaphragm were also identified in 7 NPC patients out of 100 (7%). Out of these 7 patients with metastatic NPC, 4 patients had lung metastasis and below diaphragm

metastatic lesions within the liver and abdominal lymph nodes. Two patients had hepatic and adrenal metastasis and no metastatic lesions above the diaphragm. One patient had lung metastasis and multiple abdominal and pelvic lymph nodes, hepatic, splenic and osseous metastatic lesions. The management of disease was changed based on the findings below the level of diaphragm in one subject (1.25%) with HNSCC (the patient had the primary tongue SCC and cervical lymph nodes with only lumbar metastasis) and two subjects (2%) with NPC as there are no metastatic lesions in these patients above the level of the diaphragm Figs. 1, 2, 3, and 4 show several representative cases of HNSCC and NPC.

DISCUSSION

One of the current primary indications of FDG PET/CT is evaluation of head and neck cancer patient. FDG PET/CT has been proven to be a major advance for diagnosis, initial staging, evaluation of therapy response, restaging, and evaluation of recurrence. Many recent studies reveal how PET/CT is useful in the management of patients with head and neck malignancy [6, 7-9]. The overall incidence of clinically identified distant metastases in HNSCC at presentation varies from 2% to 18% [10-12] and is

generally considered too low to warrant routine screening for distant metastases in all HNSCC patients ^[13]. However; NPC shows a high frequency of distant metastasis compared with other tumors of the head and neck with frequency of distant spread varies between 5% and 41% ^[14]. Therefore the added value of scanning below the level of the diaphragm in HNSCC is in question. The standard radiologic staging of malignancy in head and neck region involves imaging the head, neck, chest, and upper abdomen. However; FDG PET/CT scans are usually performed as a whole body scan from the base of skull to mid thighs. This protocol is attractive since the patient has already received the radiation dose associated with the FDG injection; it makes sense to scan the whole body to ensure that sites of distant disease, even if infrequent, are found.

On the other hand the rationale for the other protocol of limited above diaphragm PET/CT in HNC is that the low yield of finding abnormalities below the diaphragm is outweighed by the risk associated with missing rare metastatic lesion below the diaphragm. The expected benefits from limited above diaphragm PET/CT in HNC includes less radiation exposure to the patient, especially for the genital organs from

the CT component, allows quicker patient through-put and shorter time in the scanner for the patient. These allow more patients to be done per working day on the PET/CT scanner ^[3].

In this study we tried to answer the question "Is it mandatory to do whole body scan in evaluation of HNC patient?" The results of this study showed that metastatic lesions from HNC below diaphragm were identified in 9 patients out of 180 (5%). One patient with tongue SCC with metastatic cervical lymph nodes and synchronous rectal cancer had only metastatic osseous lesions (lumbar 2 and 3 vertebrae) below the diaphragm, which approved to be SCC metastasis by biopsy and pathological examination. The other patient had maxillary SCC and had hepatic metastasis in addition to lung metastasis.

Lesions below diaphragm were also identified in 7 patients out of 100 NPC (7%). Out of these 7 patients with metastatic NPC, 4 patients had lung metastasis and below diaphragm metastatic lesions within the liver and abdominal lymph nodes. Two patients had hepatic and adrenal metastasis and no metastatic lesions above the diaphragm. One patient had lung metastasis and multiple abdominal and

pelvic lymph nodes, hepatic, splenic and osseous metastatic lesions.

The management of disease was changed based on the findings below the level of diaphragm in one subject (1.25%) with HNSCC (the patient had the primary tongue SCC and cervical lymph nodes with only lumbar metastasis) and two subjects (2%) with NPC as there are no metastatic lesions in these patients.

Our study agreed in its conclusion with a study of Huang and Ravi Kumar [4] who retrospectively reviewed FDG PET/CT scans of 240 patients with HNSCC. Their results revealed that all patients demonstrated intrapulmonary metastases. Two patients (0.8%) had additional liver metastases, which would not have impacted on the overall management. No patient demonstrated isolated disease below the diaphragm. They concluded that a limited 'above-diaphragm' scan for early assessment following chemoradiotherapy might be safely considered. Our results agreed with result of Andrei et al; [3] who

retrospective studied 133 patients with HNSC and 26 patients with NPC and their result revealed that only two patient (1.5%), out of 133 HNSCC patients had lesions (hepatic and osseous metastases) below the adrenal glands. Metastatic lesions from NPC were identified below the adrenal glands in two patients (7.7%).

The limitations of our study include the selection bias, which is usual associated with a retrospective study and the small number of studied patients. Therefore future studies with a greater number of HNC patients may help to verify the feasibility of limited above diaphragm FDG PET/CT in HNSCC.

Conclusions: we concluded that PET/CT imaging in HNSCC of no significant added value below the level of the diaphragm. Therefore, yield (10.8%,) of relevant findings below the level of the diaphragm in NPC patients. This recommendation requires further evaluation in larger prospective studies.

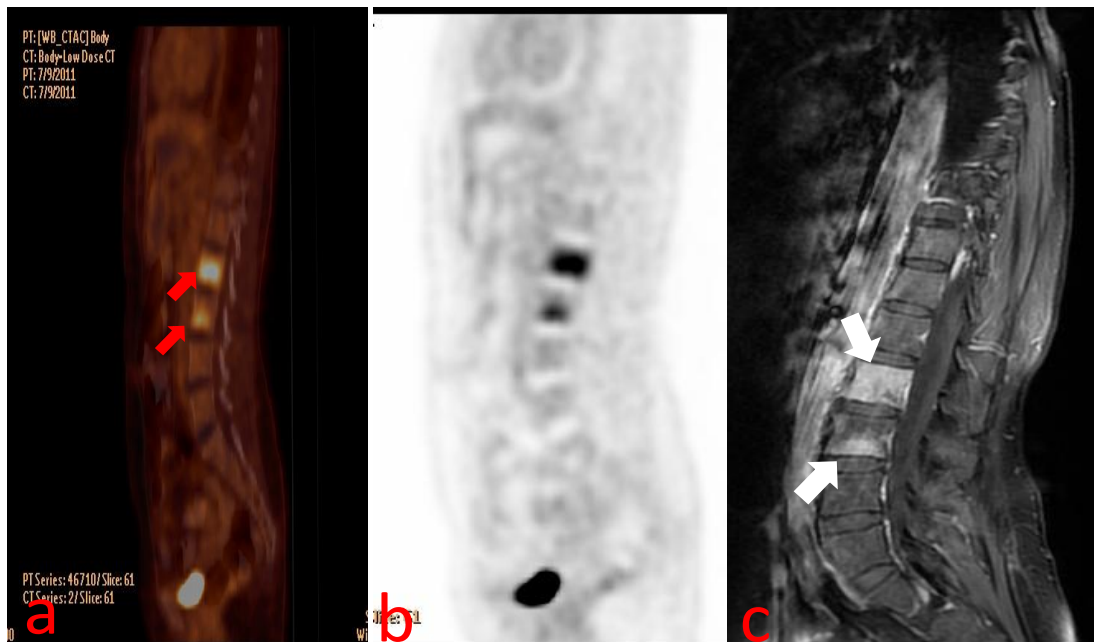


Fig. 1. A 48-year-old patient, known case of double malignancies in tongue SCC and rectal cancer post surgery and chemo-RT, recently complained of low back pain. 18F FDG PET/CT showed FDG avid hypodense osseous lesions in L2 and L3 vertebrae (red arrows) on the sagittal fused FDG PET/CT (a) and FDG PET (b) images. Post contrast lumbar spines CT showed enhanced lesions in L2 and L3 (white arrows). Biopsy was taken from these lesions and proved to be metastatic SCC.

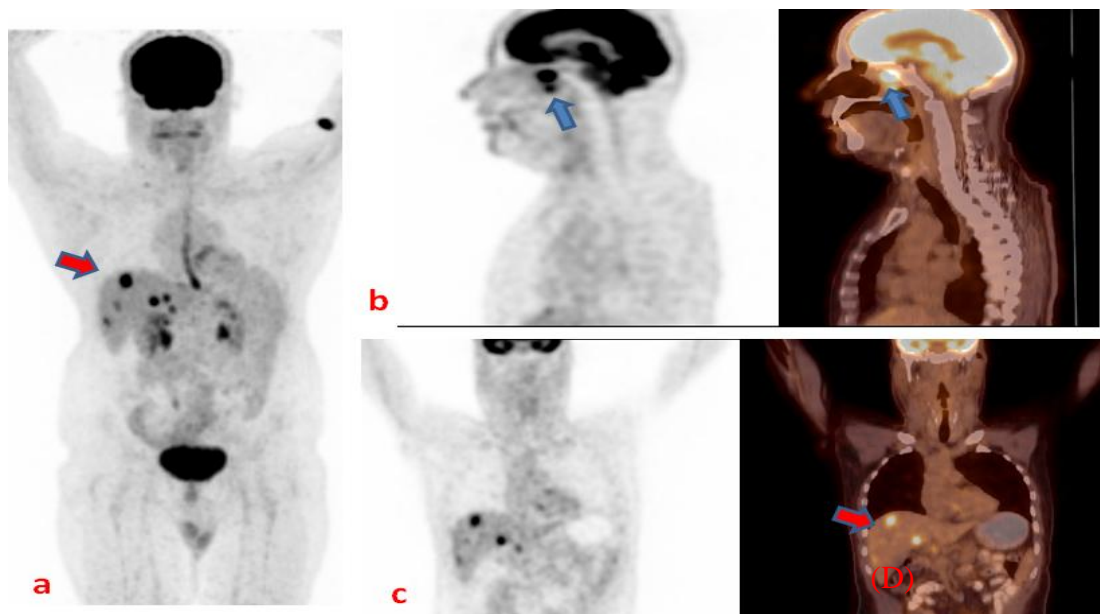


Fig. 2. A 58-year-old case of NPC post surgery and chemo-RT, for restaging. FDG PET/CT showed FDG avid metastatic hepatic lesion (red arrow), sternaosseous lesion (yellow arrow) and metastatic lung nodules (white arrow) on FDG PET MIP (a), axial (b), sagittal (c) and coronal (d) fused FDG PET/CT images.

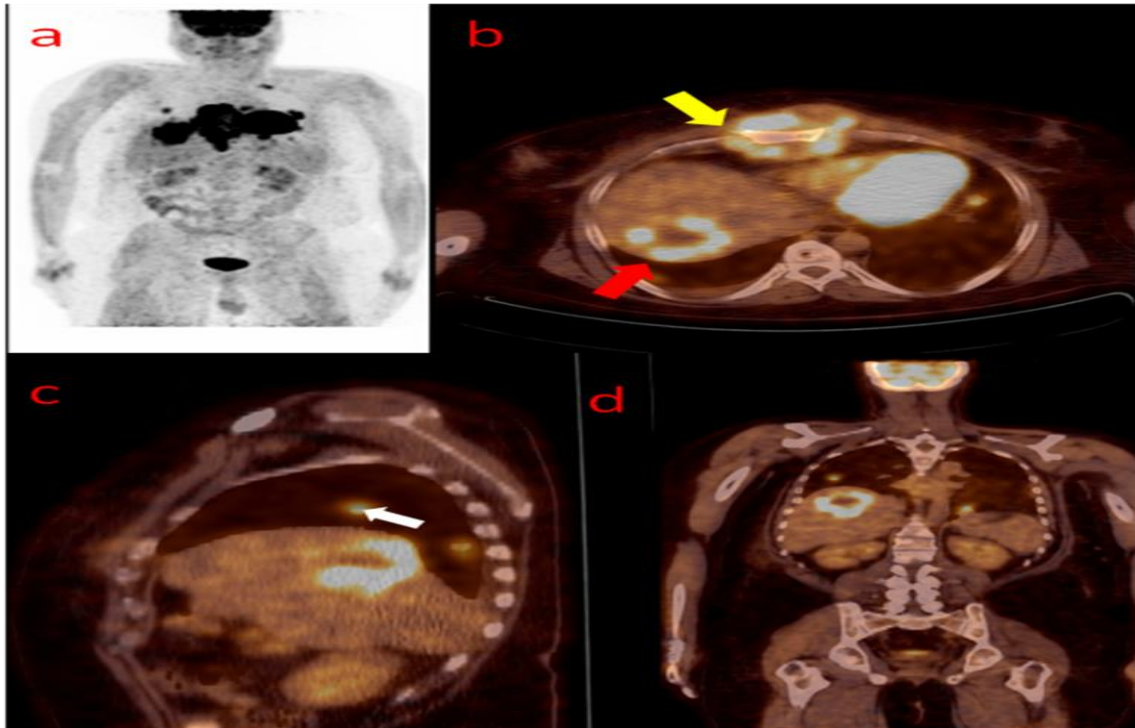


Fig.3. A 53-year-old man with biopsy proven NPC, FDG PET/CT done for staging. 18 FDG PET MIP (a), fused 18F FDG PET/CT and PET sagittal (b) and coronal (d) showed metabolically active nasopharyngeal tumor (blue arrow) with multiple metabolically active hepatic metastatic lesions (red arrow).

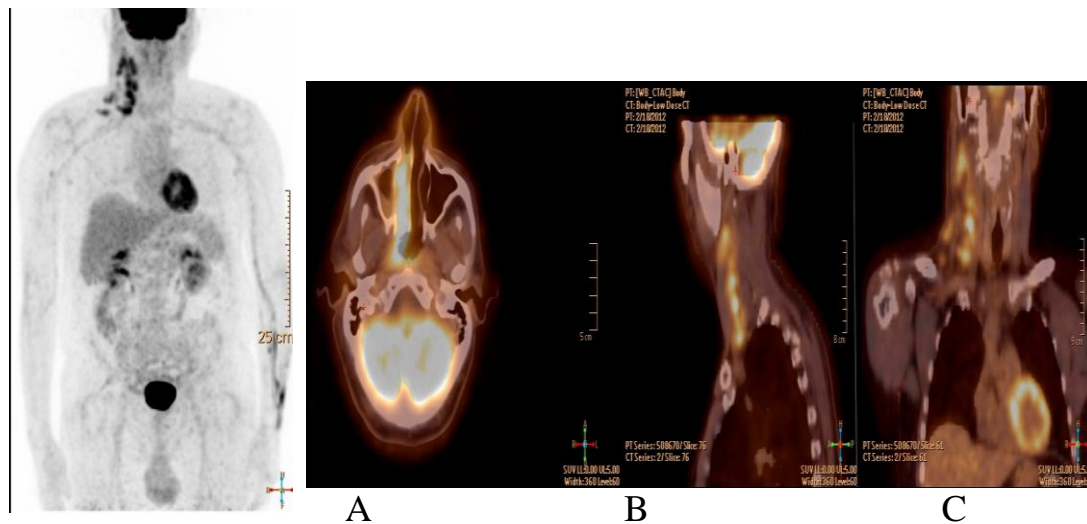


Fig. 4. A 63-year-old man with newly diagnosed NPC, FDG PET/CT done for staging. FDG PET MIP (a) and fused FDG PET/CT axial (b), sagittal (d) and coronal images (c) for the head and neck region showed metabolically active nasopharyngeal tumor with multiple metabolically active right cervical metastatic lymph nodes. Otherwise there is no distant metastasis.

REFERENCES

1. Gambhir SS Molecular imaging of cancer with positron emission tomography. *Nat Rev Cancer* 2 (9):683–693;2002 .
- 2- Clinical PET and PET/CT text book: H. Jadvar and J.A. Parker: head and neck cancer, page; 106, Springer-Verlag London Limited ; 2005.
- 3- Andrei Iagaru, Erik S. Mittra and Sanjiv S. Gambhir: FDG-PET/CT in Cancers of the Head and Neck: What is the Definition of Whole Body Scanning? *Mol Imaging Biol.* 13:362- 367; 2011.
- 4- Huang YT, Ravi Kumar AS: Potential for truncating the scan length of restaging FDG-PET/CT after chemoradiotherapy in head and neck squamous cell carcinoma. *Nuc MedCommun..May;33(5):503-508; 2012.*
- 5- Browne J, De Pierro A: A row-action alternative to the EM algorithm for maximizing likelihoods in emission tomography. *IEEE Trans Med Imag,* 15:687-699; 1996.
- 6- Agarwal V, Bft B, Johnson JT Indications for PET/CT in the head and neck. *OtolaryngolClin North Am* 41(1):23–49,2002 or 2008.
- 7- Gil Z, Even-Sapir E, Margalit N, Fliss DM Integrated PET/CT system for staging and surveillance of skull base tumors. *Head Neck* 29 (6):537–545; 2007.
- 8- Kim MR, Roh JL, Kim JS et al Utility of (18) F-fluorodeoxyglucose positron emission tomography in the preoperative staging of squamous cell carcinoma of the oropharynx. *Eur J SurgOncol* 33 (5):633–638; 2007.
- 9- Murakami R, Uozumi H, Hirai T et al Impact of FDG-PET/CT imaging on nodal staging for head-and-neck squamous cell carcinoma. *Int J RadiatOncolBiolPhys* 68(2):377–382; 2007.
- 10- Brouwer J, de Bree R, Hoekstra OS, et al. Screening for distant metastases in patients with head and neck cancer: is chest CT sufficient? *Laryngoscope.*;115:1808–1812; 2005.
- 11- de Bree R, Deurloo EE, Snow GB, Leemans CR. Screening for distant metastases in patients with head and neck cancer. *Laryngoscope.*;110:397–400; 2000.
- 12- Jäckel MC, Rausch H. Distant metastasis of squamous epithelial carcinomas of the upper aerodigestive tract: the effect of clinical tumor parameters and course of illness [in German]. *HNO.*;47:38–44; 1999.
- 13- Leibel SA, Scott CB, Mohiuddin M, et al. The effect of local-regional control on distant metastatic dissemination in carcinoma of the head and neck: results from an analysis of the RTOG head and neck database. *Int J RadiatOncolBiol Phys*;21:549–556; 1991.
- 14-Yen-Kung, Ru-Hwa, Kwan-HwaChi "Application of18F-FDG PET/CT in Nasopharyngeal Carcinoma" *Ann Nucl Med Sci* 20:21-32;2007.