

Original Paper, Oncology.

Restaging and Follow up of Seminomatous and Non Seminomatous Testicular Tumors Using F18 FDG PET/CT.

El-kholy, E¹ Fathy, H¹ and El Liethy, N².

¹Radiation oncology & Nuclear Medicine Department, ² Radiology Department, NCI, Cairo University, Egypt.

ABSTRACT:

Aim: to evaluate the role of FDG PET/CT in restaging and follow up of Seminomatous and non Seminomatous testicular tumors. **Materials and methods:** 54 patients (mean age: 34.2 ±11.8) with pathologically proven testicular cancer in whom FDG PET/CT were retrospectively assessed. Total 89 PET/CT studies were conducted in comparison to diagnostic CT. Pathological and clinical/radiological follow-up for 6-15 months duration served as standards of reference. **Results:** Seminomas type was more prevalent (64.8%). 30% of patients did not develop metastases during their course of disease. While 38 patients develop metastatic lesions (31 had abdominal nodal deposits and 5 patients had distant sites and 2 patients presented by both).

The lung was the most common site for distant metastases. All 33 patients with recurrent lesions had regional abdominal nodal deposits, while distant metastasis was more detected in 9 patients with Non Seminomatous pathology. FDG PET/CT had higher sensitivity, specificity, and accuracy of 94%, 86.5%, and 92.5% versus 76%, 85% 83%; for diagnostic CT in per patients analysis. A total of 90 lesions were reported, (62 nodal & 28 distant) metastatic lesions were analyzed. PET/CT showed good accuracy for the detection of residual/recurrent Seminomatous lesions, with an overall sensitivity and specificity of 94.7 % and 93.3 %, respectively compared to 89.2% and 56.2% for diagnostic CT, their size mean + SD (3.9+-3.1) and SUV max (7+-6.3).

Non Seminomatous distant metastases showed comparable results for both PET/CT and diagnostic CT with false negative results in small sized (mainly lung lesions). 25 patients had single PET/CT; its results with diagnostic CT were comparable in 20 patients (84%), while 29 patients with repeated 64 PET/CT studies had comparable analysis to diagnostic CT in 22 patients (~76%). In the other 7 patients (~24%), a higher value of PET/CT

in assessment of therapy response was noted. PET/CT shows CMR in 5 patients that remain stationary in CT based on size difference analysis. **Conclusion:** The current study showed that 18FDG-PET/CT is useful in re-staging & assessment of response on patients with Germ cell testicular tumor as compared to CT regarding Seminomatous abdominal nodal lesions and non Seminomatous distant disease.

Key words: FDG PET/CT, testicular, restaging, therapy response, prognosis.

Corresponding Author: El-kholy, E.

E-mail: esraa_kholy@yahoo.com.

INTRODUCTION:

Despite testicular cancer is relatively a rare tumor; it is considered the most common malignancy in young men ⁽¹⁾. It is classified into two entities, germ cell tumors and stromal tumors. Germ cell tumors is pathologically subdivided into Seminomatous and non-Seminomatous tumors, as seminomas, accounting for approximately 40% of GCTC and non-Seminomatous germ cell tumors (NSGCT) account for approximately 60% ^(2,3). Overall, the prognosis for testicular cancers is good, which makes the choice of accurate treatment intensity between under- and overtreatment often difficult, residual

masses in advanced clinical stages occur frequently but are non-vital tissue ^(4, 5). For assessing the success of chemotherapy in the presence of residual masses, especially in pure seminoma, F-18 FDG PET is an important tool, in non-Seminomatous tumors, it is hampered by the false-negative results in mature teratoma, for which reason false-negative results are a common problem ⁽⁶⁾. F-18 FDG PET performs best in predicting relapse in seminoma residuals larger than 3 cm. So far, no alternative to F-18 FDG for PET imaging of testicular cancer has been found ⁽⁷⁾.

PATIENTS AND METHODS:

The present work included retrospective analysis of 54 patients with histopathologically proven testicular tumor. They were referred to Nuclear Medicine Unit in National Cancer Institute (NCI) as part of their follow up between March. 2016 and March. 2018 for FDG PET-CT scan. Clinical and imaging follow up were extracted from the medical files, including age, sex, detailed pathology, imaging findings. **Inclusion criteria includes** age above 18 years old, histo-pathologically proved testicular cancer (with different pathological types) and patient received certain treatment according to guidelines. **Exclusion criteria** include age below 18 years, patients having double primary. All patients were informed about details of the study with a written consent approval. **FDG PET/CT Imaging Procedure:** All patients fasted for at least 4 h before the exam. Blood glucose levels did not exceed 150 mg/dL. The procedure is explained to both the patient and the parent, and any questions or concerns can be addressed as required. Scanning started 45-60 min after tracer injection of 1-1.5 mCi/kg, with a minimum dose of 37 MBq (1 mCi). (5-7 bed positions; acquisition time, 2-3

min/bed position) using a dedicated PET-CT scanner (GE, PET/CT Discovery). This camera integrates a PET scanner with a dual-section helical CT scanner and allows the acquisition of co-registered CT and PET images in one session. Intravenous contrast agent was administered in most patients except with those with certain contraindication initially, patients were examined in the supine position with arms elevated, and CT scanning was started at the level of the Cervico-thoracic region with the following parameters: 40 mAs; 130 kV; slice thickness, 2.5 mm; pitch, 1.5. The CT scans were acquired during breath holding within the normal expiration position and reached caudally to the mid tibia. PET over the same region was performed immediately after acquisition of the CT images. The CT-data were used for attenuation correction, and images were reconstructed as 5-mm slices applying a standard iterative algorithm (ordered - subset expectation maximization). **Conventional Studies:** CT whole body was used for assessment of abdominal nodal and distant metastases, especially for parenchymal pulmonary nodules in comparison with PET.

Interpretation: Images were interpreted at a workstation equipped with fusion software (advantage Window AW version 5 , GE) that provides multi-planar reformatted images and enables display of the PET images, CT images, and fused PET/CT images in any percentage relation. Side-by-side image interpretation was accomplished by 2 experienced nuclear medicine physicians.

Imaging Interpretation: Qualitative (Visual) assessment: For 18F-FDG PET/CT interpretation, any focal uptake , superior to background reference either in the primary site or other different metastatic locations (nodal, pulmonary, osseous, peritoneal or soft tissue) was interpreted as positive or abnormal FDG uptake.

Quantitative assessment: The PET slices, around the areas demonstrating the greatest accumulation of 18F-FDG and away from any nearby overlapping activity. Another sizable ROI was drawn over the normal liver where its max SUV was considered reference activity for further quantitative analysis.

Data Analysis was performed depending on the following criteria: True positive PET/CT results: 18F FDG PET/CT and CT agreed, metabolically active FDG avid metastatic lesion of SUV max higher than

the reference hepatic activity or positive tissue pathology in unascertained lesions.

True negative PET/CT results: CT and PET/CT results within one month agreed with clinical follow up (after 6-12 months from radiological investigations) were free i.e no newly developed relevant symptoms or signs.

False positive PET/CT results: Metabolically active FDG avid lesion proved to be benign using pathological analysis after excision or follow-up studies.

False negative PET/CT results: Mass of low metabolic activity of SUV max that show significant increase in FDG uptake on the follow up images, pathology by biopsy or after excision was malignant or follow up CT revealed disease progression.

Statistical Analysis: The sensitivity, specificity, negative predictive value, positive predictive value, and accuracy of conventional imaging and PET/CT were calculated on the basis of the true-positive and true-negative findings as described in the same anatomic region with a lesion-based and a patient-based analysis. The McNemar test (χ^2 test) was used for comparison of the sensitivity and specificity of CT with those of fused PET/CT (and for calculation of localizing accuracy comparing diagnostic CT with fused PET/CT).

RESULTS:

Consecutive patients with testicular cancer referred to perform PET/CT examination in the period between March, 2016 and March, 2018 at National Cancer Institute Egypt (NCI) were analyzed in the present study.

A total number of 54 patients with total 89 PET/CT scans were included.

The age of patients ranged from 18 to 62 years with a mean of 34.2 ± 11.8 . Their clinico-pathological data were analyzed in *Table (1)*.

Table (1): Demographic data of included 54 patients with testicular cancer.

| Criteria | Data Analysis |
|----------------------------|---|
| Age | (mean \pm SD) 34.2+_11.8SD |
| Pathology | Seminoma NSGCT Mixed |
| Stage | Ia Ib Is IIa IIb IIc IIIa IIIb IIIc |
| Post orchiectomy treatment | Surveillance Radiotherapy Chemotherapy Chemotherapy + RPLND RPLND |

*NSGCT = non-Seminomatous germ cell tumors.

Seminomas type was prevalent among the included patients (64.8%), while 11 patients had NSGCT, with 8 mixed type. According to clinical staging, stage II was more prevalent including 25 patient followed by stage I (22 patients), while 7 patient were had stage III. 16 patients (29.6%) had not developed any nodal or

metastatic lesions during their course of disease. Among the remaining 38 patients 31 (81.5%) had abdominal nodal deposits, 5 patients had distant sites and 2 patients presented by both. The lung was the most common site for distant metastases, while two patients had metastatic soft tissue nodules (*Table 2*).

Table (2): Distribution of metastatic disease in testicular cancer patients (n=54).

| | Number of patients (total-54) | Percent (%) |
|--|----------------------------------|----------------|
| Non Metastatic | 16 | 29.6 % |
| Metastatic | 38 | 70.4 % |
| Abdominal nodal metastases | 31 | 81.5 % |
| Distant metastases | 5 | 13 % |
| Abdominal nodal + distant sites | 2 | 7.9 % |

There were 33 tumor-positive and 21 true negative patients as classified by the gold standard. Clinical follow-up and histology were served as the gold standard in 45 and 9 cases, respectively. All 33 patient with recurrent Seminomatous lesions had regional abdominal nodal deposits (except for 1 patient had additional soft tissue nodules), while the distant metastasis were

detected only on patients with Non Seminomatous pathology. (**Table 3**) 31 patients had regional (Abdominal) lymph node metastases, and the lung was the most common site for distant disease presented in 5 patient. One patient had wide spread metastatic deposits involving the lung, liver, pancreatic infiltration, and osseous and soft tissue metastases.

Table (3): Distribution of sites of metastatic lesions in patients with Seminomatous and Non Seminomatous recurrence (n=38).

| | Seminomatous | Non Seminomatous | Total |
|---------------------------|--------------|------------------|-------|
| Nodal Metastases | | | |
| Abdomino-pelvic | 20 | 13 | 33 |
| Mediastinal | 1 | 2 | 3 |
| Supraclavicular | 1 | 1 | 2 |
| Distant metastases | | | |
| Pulmonary-pleural | 1 | 5 | 6 |
| Hepatic | 0 | 1 | 1 |
| Osseous | 0 | 1 | 1 |
| Pancreas | 0 | 1 | 1 |
| Soft tissue nodules | 1 | 1 | 2 |

Among 33 patients with positive recurrence, PET/CT identified 31 true positive and the other two patients considered false negative as the initial low grade metabolic activity demonstrated over para-aortic and aorto-caval lymph nodes significantly increased on 3-6 months follow up study. 19 patients were true negative on PET/CT, depending on their follow up that showed no evidence of recurrent lesions over the follow-up period with decline of their serum tumor marker level. The remaining 2 patients were considered false positive one of them proved by histo-pathology and the other

showed no evidence of positive findings on follow up studies.

Regarding CT interpretation, 29 true positive patients were detected, while 4 patients showed false negative results, all of them proved to have small sized abdominal nodal metastases. The false positive results are related to large sized nodal lesions with no corresponding FDG activity which regressed /stationary on serial follow up studies.

On a per-patient basis, sensitivity, specificity, positive and negative predictive values as well as diagnostic accuracy are illustrated in **Tables (4)**.

Table (4): Comparison of overall different detection parameter of PET/CT & conventional modalities Interpretations on a Per-Patient basis (*n*. 54).

| | Sensitivity | Specificity | PPV | NPV | Accuracy |
|---------------------|--------------------|--------------------|------------|------------|-----------------|
| PET/CT | 94 | 86.4 | 91.2 | 90.5 | 92.5 |
| Conventional | 87.9 | 76.2 | 85.3 | 80.0 | 83.3 |

PET/CT showed good accuracy for the detection of residual/recurrent Seminomatous lesions, with an overall sensitivity and specificity of 94.7 % and 93.3 %, respectively compared to 89.2% and 56.2% for diagnostic CT. Most of these lesions were nodal metastases, their size mean + SD (3.9+-3.1) and SUV max

(7+-6.3). Regarding the distant metastases of non Seminomatous disease, there was a comparable result for both PET/CT and diagnostic CT; false negative findings were almost related to the small size of lesions (mainly the lung) with its partial volume effect (**Tables 5**).

Table (5): Comparison of overall different detection parameter of PET/CT & conventional modalities Interpretations for abdominal nodal metastases (n. 33).

| | Sensitivity | Specificity | PPV | NPV | Accuracy |
|---------------------|-------------|-------------|------|------|----------|
| PET/CT | 94.7 | 93.3 | 97.3 | 87.5 | 96.0 |
| Conventional | 89.2 | 56.2 | 82.5 | 69.2 | 80.0 |

A total 89 PET/CT studies were reviewed for 54 patients included in our study. 25 patient had single PET/CT, its results with diagnostic CT were comparable in 20 patients (84%), 12 were true positive on both modalities for the presence of metastatic abdominal nodal lesions of most patients except for one patient with pulmonary metastases, the other 8 patients were identified as true negative on both scans. 4 patients had residual sizable lymph nodes which show no corresponding FDG activity and kept stationary on follow up CT.

Regarding follow up of the 29 patients with repeated 64 studies, Positron Emission

Tomography (PET) Response Criteria in Solid Tumors (PERCIST 1.0) is used to assess the response. The results of diagnostic CT scan and PET/ CT were comparable in 22 patients (~76%); 11 patients had CMR, 6 patients had PMD and three patients had RMD in PET/CT. In the other 7 patients (~24%), a higher value of PET CT in assessment of therapy response was noted compared to that of diagnostic CT results. In 5 patients, PET/CT shows CMR while diagnostic CT results were SD because the size of metastatic lymph nodes which kept stationary compared to the SUV max that shows marked regression in **Table (6) & Figure (1,2).**

Table (6): Results of follow up 18F-FDG PET/CT and CT scan.

| Number of Patients | PET/CT | CT |
|----------------------------------|-------------------------------|---------------------|
| Comparable Results (n.22) | | |
| 11 | Complete metabolic remission | Complete remission |
| 3 | Partial metabolic remission | Partial remission |
| 6 | Progressive metabolic disease | Progressive disease |
| 2 | Stable metabolic disease | Stable disease |
| Discrepant Results (n.7) | | |
| 5 | Complete metabolic remission | Stable disease |
| 2 | Partial metabolic remission | Stable disease |
| Total | 29 | 29 |

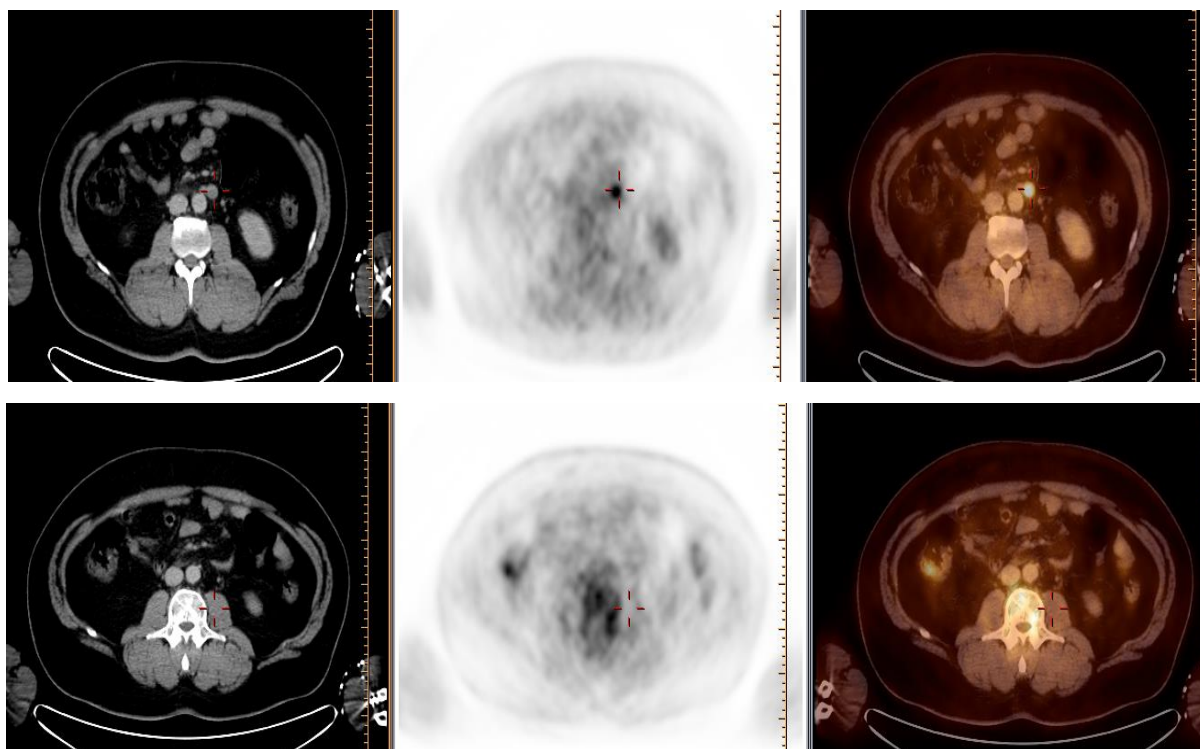


Fig. (1): 25 year-old male patient with Seminomatous testicular cancer (a) showed metastatic left para-aortic lymph node, with SUVmax~7.5. (b) Follow up PET/CT after 3 months of chemotherapy showed CMR.

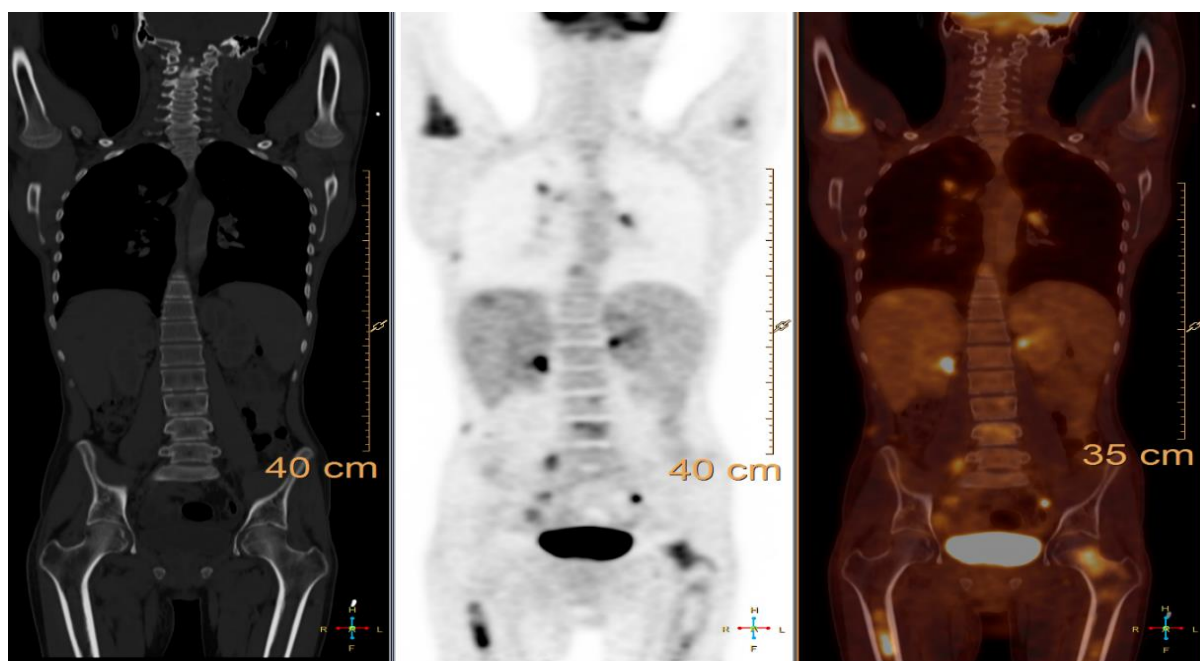


Fig. (2): 34 years old male with non seminomatous testicular cancer. Follow up PET/CT shows multiple metastatic pleuro-pulmonary, nodal, hepatic, pancreatic and osseous deposits.

DISCUSSION:

One of the important prognostic factors in Germ cell tumors (GCTs) is the pathology, the Seminomatous type are associated with a good outcome, while the Non Seminomatous tumors are generally more aggressive and associated with poor prognosis ⁽³⁾. The standard imaging modality used in diagnosis is the CT which lacks the ability to detect tumor in normal sized LNs and also can not differentiate between residual viable tumor tissue from post therapy fibrosis. An advantage of 18F-FDG PET/CT is that it is a whole-body scan, including bone marrow and different organs in one step, also can differentiate between viable tissues from fibrosis & can detect active malignant tissue in small sized LNs ^(4, 5). The aim in this study was to retrospectively evaluate the role of PET/CT in restaging of testicular tumors (Seminomatous and non Seminomatous) in the period from March 2015 to March 2018 in national cancer institute. PET/CT showed good overall sensitivity and specificity in seminoma while its sensitivity in NS forms was suboptimal. In the current study the metastatic abdominal nodal lesions was the most common site, in which 31 patients had abdominal nodal lesions from 38 patients with metastatic lesions, 5 patients had visceral deposits and the remaining 2 patients has both. These results are matched with *Hitchins et al.* who reported that in a retrospective study

of 297 patients, the incidence of bone metastases in testicular and extra gonadal GCTs was 3% at presentation and 9% at relapse, where all patients had synchronous retroperitoneal lymph node or lung metastases ⁽⁶⁾. Also in our study the accuracy of detecting residual viable tumor by PET/CT is more superior to the conventional CT, we found that a significant value of PET/CT in evaluation of treatment response. We noted that in 5 patients, PET/CT shows CMR and no uptake keeping with resolution of the disease while the CT results were stationary disease this is because of the size of the metastatic lymph nodes which were rather stationary and during further follow up proved to be remitted lesions and the CT results were false positive. *De Santis et al.*, in a study of 56 Seminomatous GCT patients, have shown that PET is the best predictor of viable disease in residual masses with a sensitivity of 80% and specificity of 100%, in comparison to CT which has a sensitivity of 70% and specificity of 74% ⁽⁷⁾.

Similar results were confirmed by a meta-analysis ⁽⁸⁾. While the use of PET in non-Seminomatous GCT is controversial. In NSGCT, PET has a PPV of 91% and NPV of 62% in differentiating viable from non-viable disease. This means that a negative PET study cannot exclude the presence of disease ⁽⁹⁾.

In other words PET has a definite role in the evaluation of seminoma, but cannot predict the presence of disease in NSGCT with negative PET study according to *Agrawal and Rangarajan* ⁽¹⁰⁾.

Their results are matched with our study, in which the overall sensitivity was 94% and the specificity was 86.4%.

Despite the widely increasing use of PET/CT for all cancers, the clinical role of this imaging modality in germ cell testicular cancer (GCTC) is still unclear, since controversial results have been achieved by previous studies and few large trials have investigated its potential application in this setting. Yet, the clinical use of 18F-FDG PET/CT is currently recommended in restaging process of seminoma to differentiate viable residual tumors from necrosis/fibrosis after chemotherapy ⁽¹¹⁾.

In NSGCT, *De Santis, et al*, unequivocally found that PET predicted viable tumor within the residual lesions with a high measure of diagnostic accuracy, except in very small residuals. Unfortunately, FDG PET failed to distinguish between mature teratoma and necrosis/fibrosis, because both accumulate very little or no FDG. Therefore, FDG PET does not help in, however in SGCT FDG PET/ CT studies for the evaluation of pure seminoma residuals can be regarded as a standard tool for clinical decision-making ⁽¹²⁾.

This point in NSGCT can't be assessed in our study as the patients with non Seminomatous pathology were small in only 19 patients.

FDG-PET may have a role in resolving equivocal CT findings, as the slightly higher sensitivity with FDG-PET may be useful in evaluating borderline lymph nodes ⁽¹³⁾. Alternatively, targeted interval CT provides an option to assess growth of the borderline nodes using a lower dose of radiation. Importantly, clinicians must be aware of the limitations of FDG-PET if it is used as a problem-solving tool to resolve CT findings, for example, inflammatory lesions can also be FDG-avid on PET.

A study published in 2010 assessed the efficacy of PET/CT fusion imaging to detect testicular cancer metastases in a series of 49 patients ⁽¹⁴⁾.

These authors found that the sensitivity and specificity of PET/CT were superior to either study alone in identifying and following metastatic disease. Although differentiation between teratoma and fibrosis or necrosis could not be achieved using PET/CT (as with other commonly used nuclear imaging modalities), detection and localization of micro metastatic disease, which would otherwise be missed on CT, were improved. As discussed previously, nuclear imaging has found an application in staging of Seminomatous GSTs in the post chemotherapy setting.

A number of approaches have been developed to improve the accuracy in case of restaging of the NSGCTs, the use of dynamic FDG scanning, which evaluates the kinetic rate constants of FDG uptake, was first evaluated in a 1999 study by *Sugawara et al.* ⁽¹⁵⁾. In particular, these authors evaluated various parameters of FDG uptake kinetics (transfer from bloodstream to tissue [k1], phosphorylation [k2], and transfer from tissue back to the bloodstream [k3]) and found that k1 was significantly elevated in mature teratoma compared with necrotic tissue. These findings led to the suggestion that patients with NSGCT who have a negative PET and a low k1 could be observed, whereas those with a negative PET and an elevated k1 should undergo resection for presumed teratoma.

Because it is difficult to implement dynamic FDG scanning in clinical practice because of its time-consuming nature, to our knowledge, this concept has not been tested in any additional clinical studies.

In our study the sensitivity, specificity, PPV, NPV and accuracy are 94%, 86.4%, 91.2%, 90.5% and 92.5% respectively for the PET/CT compared to 87.9%, 76.2%, 85.3%, 80% and 83.3% for the CT which is concordant with many studies, the higher accuracy in PET/CT is due to its ability to detect viable tumor in normal sized and small sized nodes and the ability to differentiate between fibrosis and residual viable tumors.

Spermon et al reported that in primary staging, FDG-PET has no benefit over CT. In re-staging, a negative FDG-PET result predicts fibrotic residual mass in Seminomatous GCT. Moreover, it could be useful to predict fibrotic residual mass in NSGCT in those patients with no teratoma component in their primary tumor ⁽¹⁶⁾. In one study the sensitivity and specificity of PET/CT was reported to be 87% and 94%, respectively, compared to 73% and 94% for CT ⁽¹⁷⁾.

In another study done by *Becherer et al*, the sensitivity and specificity for CT is lower than that for PET/CT in post therapy assessment and detection of relapse ⁽¹⁸⁾.

Also, Bachner et al, in their study of 177 patients post chemotherapy referred to do PET/CT for assessment of treatment response confirms the high specificity, sensitivity, and NPV of FDG-PET for evaluating post chemotherapy seminoma residuals, spares patients unnecessary therapy ⁽¹⁹⁾. Also in another study, 92 patients were underwent PET/CT that revealed true positive in 49, false positive in 10, true negative in 30 and false negative in 3 patients. 18F-FDG PET/CT showed sensitivity, specificity, positive predictive value, negative predictive value and accuracy of 94.2%, 75.0%, 83.0%, 90.9% and 85.8% overall; 90.0%, 74.0%, 72.0%, 90.9% and 80.8% in Seminomatous GCT; and 96.8%, 76.9%, 91.1%, 90.9% and 91.1% in non-Seminomatous GCT, respectively.

Difference in PET/CT accuracy for Seminomatous and non-Seminomatous GCTs was not significant ($p = 0.263$). PET/CT demonstrated disease in 13 patients with negative/equivocal conventional imaging findings⁽²⁰⁾.

Giorgia et al reported that 51 seminoma and 70 non seminoma (NS), 121 cases were reviewed. PET/CT showed good sensitivity and specificity for seminoma lesion detection (92 % and 84 %, respectively), but its sensitivity was lower for NS forms (sensitivity and specificity 77 % and 95 %, respectively)⁽²¹⁾, also this is matched with our study. Regarding the abdominal nodal metastases in the current study, the PET/CT sensitivity, specificity, positive predictive value, negative predictive value and accuracy were 94.7%, 93.3%, 97.3%, 87.5% and 96% respectively, while for the conventional CT they were 89.2%, 56.2%, 82.5%, 69.2% and 80% respectively with higher accuracy in PET/CT,

again as the functional imaging can detect viable tumor in spite of normal or small sized nodes while the false positive results in the CT is due to depending on size which may be metabolically inactive and the residual is fibrotic and remitted which proved to be false positive by the follow up and pathology results in limited cases, these findings are matched with most of the previous studies which were done, we need more prospective studies and trials to establish the role of PET/CT in GCTs, the limited number of patients and the heterogeneous group are limiting factors in our study.

CONCLUSION:

The current study showed that 18FDG-PET/CT is useful in re-staging & assessment of response on patients with Germ cell testicular tumor as compared to CT regarding Seminomatous abdominal nodal lesions and non Seminomatous distant disease.

REFERENCES:

1. **Heidenreich A, Weissbach L, Holtl W, et al.** Organ sparing surgery for malignant germ cell tumor of the testis. *J. Urol.* 166: 2161–2165; 2001.
2. **Secil M, Altay C, Basara I.** State of the art in germ cell tumor imaging, *Urologic Oncology: Seminars and Original Investigations*, Volume 34, Issue 3, Pages 156-164; 2016.
3. **Beyer J, Albers P, Altena R, et al.** Maintaining success, reducing treatment burden, focusing on survivorship: highlights from the third European consensus conference on diagnosis and treatment of germ-cell cancer. *Ann. Oncol.* 24: 878–888; 2013.
4. **International Germ Cell Cancer Collaborative Group.** International germ cell consensus classification: a prognostic factor-based staging system for metastatic germ cell cancers. *J. Clin. Oncol.* 15: 594–603; 1997.
5. **Oldenburg J, Fosså S.D, Nuver J, et al.** Testicular seminoma and non-seminoma: ESMO Clinical Practice Guidelines for diagnosis, treatment and follow-up; *Annals of Oncology* 24 (Supplement 6): vi125–vi132; 2013.
6. **Hitchins RN, Philip PA, Wignall B, et al.** Bone disease in testicular and extra gonadal germ cell tumors. *Br. J. Cancer.* 58: 793–6; 1988.
7. **De Santis M, Becherer A, Bokemeyer C, et al.** 2-18fluoro-deoxy-D-glucose positron emission tomography is a reliable predictor for viable tumor in post chemotherapy seminoma: An update of the prospective metacentric SEMPET trial. *J Clin Oncol.* 22:1034–9; 2004.
8. **Zhao JY, Ma XL, Li YY, et al.** Diagnostic accuracy of 18F-FDG-PET in patients with testicular cancer: A meta-analysis. *Asian Pac. J. Cancer Prev.* 15:3525–31; 2014.
9. **Kollmannsberger C, Oechsle K, Dohmen BM, et al.** Prospective comparison of [18F] fluorodeoxyglucose positron emission tomography with conventional assessment by computed tomography scans and serum tumor markers for the evaluation of residual masses in patients with non-Seminomatous germ cell carcinoma. *Cancer.* 94:2353–62; 2002.
10. **Agrawal A and Rangarajan V.** Appropriateness criteria of FDG PET/CT in oncology; *Indian J. Radiol. Imaging.* Apr-Jun; 25(2): 88–101; 2015.
11. **Albono D, Cabelli F, Quartuccio N, et al.** PET/CT for the diagnostic assessment of patients with testicular cancer. *Clin. Transl. Imaging.* Volume 6, Issue 3, pp 217–221; 2018.

12. **De Santis M, Maj-Hes A and Bachner M.** Positron Emission Tomography (PET) in Germ Cell Tumors (GCT), chapter 28:305-313; 2009.
13. **Honecker F, Aparicio J, Berney D, et al.** ESMO Consensus Conference on testicular germ cell cancer: diagnosis, treatment and follow-up *Annals of Oncology*, Volume 29, Issue 8, 1, Pages 1658–1686; 2018.
14. **Sterbis JR, Rice KR, Javitt MC, et al.** Fusion imaging: a novel staging modality in testis cancer. *J. Cancer*.1:223–229; 2010.
15. **Sugawara Y, Zasadny KR, Grossman HB, et al.** Germ cell tumor: differentiation of viable tumor, mature teratoma, and necrotic tissue with FDG PET and kinetic modeling. *Radiology*; 211:249–256; 1999.
16. **Spermon JR, De Geus Oei LF, Kiemeny L.A.L.M, et al.** The role of 18fluoro-2-deoxyglucose positron emission tomography in initial staging and re-staging after chemotherapy for testicular germ cell tumors; *BJUI* Volume 89, Issue 6, 549-556; 2002.
17. **Cremerius U, Wildberger JE, Borchers H, et al.** Does positron emission tomography using 18-fluoro-2-deoxyglucose improve clinical staging of testicular cancer? Results of a study in 50 patients. *Urology*. 54:900–4; 1999.
18. **Becherer A, DeSantis M, Karanikas G, et al.** FDG PET is superior to CT in the prediction of viable tumour in post-chemotherapy seminoma residuals; *European Journal of Radiology* Volume 54, Issue 2, Pages 284-288; 2005.
19. **Bachner M, Loriot Y, Gross-Goupil M, et al.** 18fluoro-deoxy-D-glucose positron emission tomography (FDG-PET) for post-chemotherapy seminoma residual lesions: a retrospective validation of the SEMPET trial *Annals of Oncology*, Volume 23, Issue 1, Pages 59–64; 2012.
20. **Sharma P, Jain T.K, Parida G.K, et al.** Diagnostic accuracy of integrated 18F-FDG PET/CT for restaging patients with malignant germ cell tumors; *BJR*, Volume 87, Issue 1040; 2014.
21. **Zucchini G, Nicolini S, Berselli A, et al.** 18F-FDG PET/CT impact on testicular tumors clinical management; *European Journal of Nuclear Medicine and Molecular Imaging* , Volume 41, Issue 4, pp 668–673; 2014.